CHAPTER IV

GENERAL ANATOMY

	Page
Introductory remarks	65
Methods of study	65
Organs underlying the shell	66
Organs underlying the mantle	70
The visceral mass	71
Nervous system	71
Anatomical peculiarities	72
Bibliography	72

Before proceeding with the detailed description of the structure and function of various organs in the oyster, it appears desirable to present a general anatomical picture of this mollusk and to show the arrangement and topography of the various systems of organs.

The anatomy of edible oysters is described in several papers. Brooks (1905), Moore (1898), Churchill (1920), and Galtsoff (1958) give general accounts of the anatomy of *C. virginica*. The structure of the European oyster, *O. edulis*, is described by Orton (1937), Ranson (1943), and Yonge (1960); a brief and partial description of the anatomy of *C. angulata* by Leenhardt (1926) includes the histology of the species. The structure of the Bombay oyster, *O. cucullata*, is described by Awati and Rai (1931); and a short anatomical sketch of the Australian oyster, *O. commercialis*, is given by Roughley (1925).

The anatomical sketch of an adult *C. virginica* given in this chapter describes the principal organs of the oyster as they can be seen by dissecting the mollusk and examining the preparation under a low-power microscope. Details that can be observed by sectioning, staining, and reconstruction are described in the chapters of this book dealing with the respective organ systems.

METHODS OF STUDY

Successful dissection of the oyster depends to a considerable degree on the condition and shape of the specimen selected for study. It is convenient to work with broad and large oysters measuring about 4 to 5 inches in height and containing lean meats. In fat or in sexually mature specimens the large quantities of glycogen and of sex cells covering the organs make their anatomy difficult to trace. Oysters most suitable for anatomical study are those which have completed spawning but have not yet accumulated much glycogen. In New England waters such oysters can be found in September and early October.

For dissection the oyster should be opened by removing its flat (right) valve, a process facilitated by first narcotizing the oyster. Narcosis eliminates the necessity of forcibly prying apart the valves, a manipulation which in the hands of an inexperienced person frequently results in injury of the underlying tissues or, even more often, to the hand of the operator by the sharp edge of the shell. Another advantage of working with a fully narcotized specimen is that the organs and tissues remain fully expanded in their normal position and are undistorted by contraction.

The best method of narcotizing is to use technical magnesium sulfate (Epsom salt) as follows: The oyster is thoroughly washed and scrubbed to remove fouling organisms and then placed in a suitable container, about 8 to 9 inches in diameter and 3 inches deep, filled with sea water. During the first 24 hours small quantities of Epsom salt are gradually added until a concentration between 5 to 10 percent is reached, then the oyster is left undisturbed for another 24 or even 48 hours at room temperature. The magnesium sulfate should be added very gradually because an excess of it at the beginning of narcosis may cause the oyster to close its valves and thus prolong the process. Additional amounts of salt may be added because oysters tolerate much higher concentrations of magnesium sulfate and recover from it upon being placed in running sea water. Completely narcotized oysters do not respond to touch or prick at the edge of the mantle.

With the narcotized oyster grasped in the hand, right valve uppermost, a knife is inserted between

the mantle and the shell and carefully pushed above the meat toward the adductor muscle, its edge always at a sharp angle to the inner surface of the valve. Actually it is preferable to move the oyster right and left, while gently pressing it against the edge of the knife, rather than to move the knife itself. After the attachment of the adductor muscle to the shell is severed, the flat, right valve is lifted up until the ligament breaks and the oyster is exposed in the cupped valve which retains sea water. (In oyster bars and restaurants raw oysters are usually served on the right (flat) valve and the cupped left valve is removed.) If it is necessary to open an unnarcotized oyster, I prefer first to break the ligament with a screwdriver, then to lift the valve carefully and cut the adductor muscle. This method reduces the chances of cutting the visceral mass.

Dissection is much facilitated by allowing the tissues to harden in 3 percent formalin for at least 1 day. For tracing the digestive tract and the blood vessels I recommend, furthermore, the injection of these systems with colored moulage latex. For study of the digestive tract the following method gives satisfactory results: the mouth of the oyster is exposed by cutting out a small triangular section of both valves and pushing up the underlying tissues (the mantle cap). Blue or red latex diluted with about 20 percent water is injected into the mouth through a wide glass pipette slightly flattened at the tip and supplied with rubber bulb. During the injection the oyster is held in a vertical position. Sometimes it is difficult to fill the entire digestive tract with latex injected through the mouth. An additional injection can then be made through the anus with a 2-ml. capacity hypodermic syringe, preferably one of metal since latex rapidly adheres to glass and causes the plunger to stick.

For injecting blood vessels through the ventricle or auricles I prefer to use either latex diluted with about 30 percent of water or vinyl resin solution. Injection should be completed without interruption in one operation, after which the injected specimen is immediately placed in 5 percent formalin in tapwater and left undisturbed for several hours or overnight to allow complete setting of the latex or plastic. Preparations may be indefinitely preserved in 3 to 5 percent formalin.

Various cavities and chambers of the oyster body can be advantageously studied by making plaster of paris casts. The valves of a live oyster are forced apart by inserting an oyster knife at the ventroposterior margin of the shell and gradually rotating the knife until its edge is perpendicular to the surface of the valves. The valves should be opened very slowly to avoid tearing the adductor muscle. After a small wooden wedge is inserted to prevent closing of the valves, freshly made plaster of paris paste of the consistency of heavy cream is injected into the cloaca and into the opening of the promyal chamber. From time to time the injected specimen is tapped gently against the table to insure complete penetration of the plaster into the smallest ramification of the gill tubes. After the filling with plaster of paris is completed, the wedge is removed and the valves are pressed together. The preparation is left undisturbed for 24 hours. After the plaster of paris has hardened the shells and the soft parts of the body are removed, the cast is dried for 24 hours at 56° C. and finally may be dipped in a hot mixture of beeswax and turpentine to prevent breaking of the finest ramification of the replicas.

ORGANS UNDERLYING THE SHELL

After the valve is removed, the body of the oyster is seen to be covered with a soft membrane called the mantle (figs. 71, 72). The mantle is a bisymmetrical organ. Its left and right folds are joined together at the dorsal edge where small and slightly pigmented fold (not shown in the figure) marks the position of the ligamental ridge, a special organ which secretes the ligament. The joint portion of the two lobes forms a cap which covers the mouth and its associated structures (fig. 71, m.). The remaining mantle edges are free except for a point at the extreme ventral margin (f.) where the two opposing lobes are fused together to form a wide funnel-like channel, the cloaca (fig. 72, cl.).

The edge of the mantle consists of three protruding fringes, two of which, the outer and the middle, are beset with highly sensitive tentacles (t.). The tentacles and the edge of the mantle are commonly pigmented.

The parts of the mantle not attached to underlying organs enclose a large space filled with sea water and known as the mantle cavity. Sometimes the open space under the mantle is referred to as the shell cavity and the sea water retained in it as the shell liquor. The space between the mantle and the gills is often called the "gill cavity,"

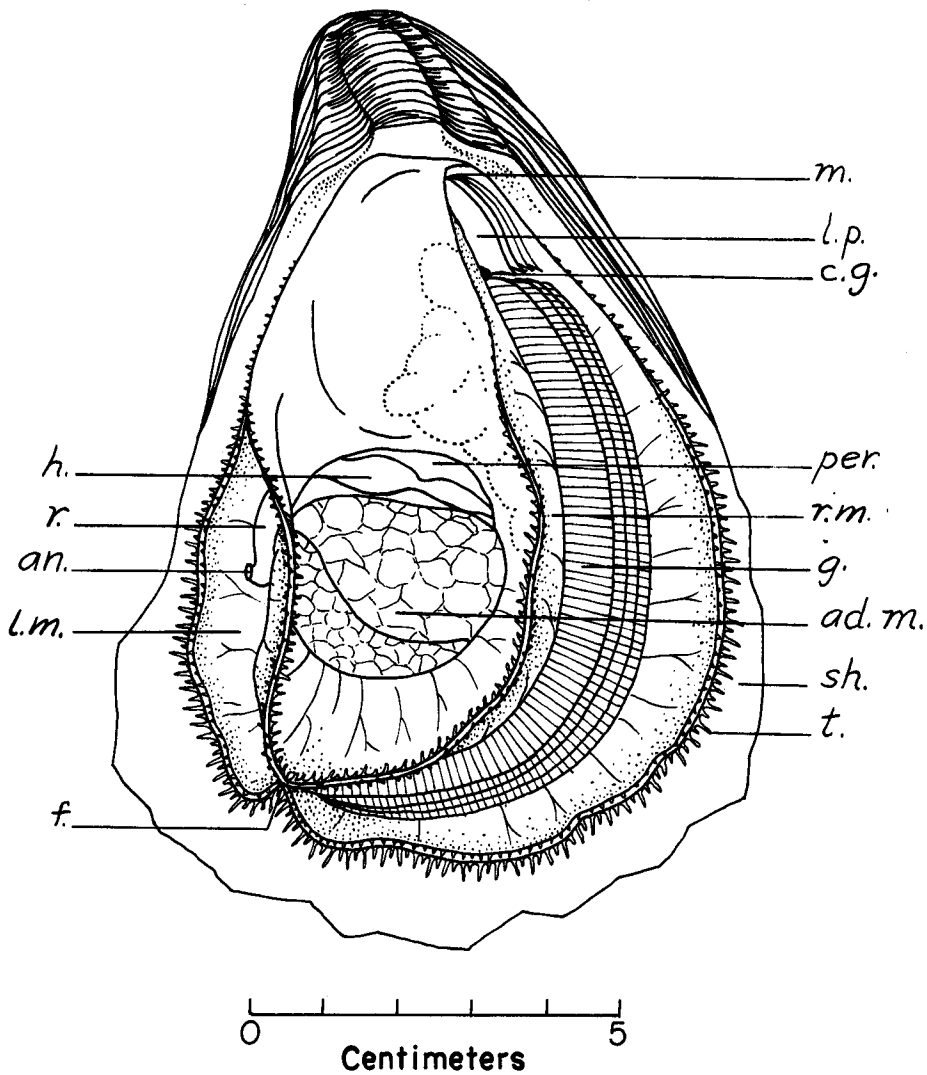

FIGURE 71.—Organs of *C. virginica* seen after the removal of right valve. ad.m.—adductor muscle; an.—anus; c.g.—cerebral ganglion; f.—fusion of two mantle lobes and gills; g.—gills; h.—heart; l.m.—left mantle; l.p.—labial palps; m.—mouth; per.—pericardium; r.—rectum; r.m.—right mantle, sh.—shell; t.—tentacles. The right mantle contracted and curled up after the removal of the right valve, exposing the gills. Portion of the mantle over the heart region and the pericardial wall were removed. Drawn from live specimen.

an undesirable term because of possible confusion with the inner spaces (cavities) of the gills. The correct terminology for the latter is water tubes and gill chambers. The expression mantle cavity seems to be more appropriate than the shell cavity. As to the shell liquor, the term is well established, especially in papers dealing with the bacteriology of the oyster and, therefore, it should be retained.

Under normal conditions the mantle underlies and adheres slightly to the shell, the secretion of which is its principal function. As will be shown later, this organ also participates in several other functions: it controls the flow of water for respiration and feeding; plays an important role in female spawning; and receives and transmits sensory stimuli.

In a living oyster the mantle cavity is always full of sea water. As the shell is closed the surplus water is ejected, but that remaining in the free spaces between the mantle lobes (fig. 73, m.c.) keeps the enclosed organs constantly bathed in water.

Various products of oyster metabolism accumulate in the shell liquor as well as considerable quantities of mucus and blood cells discharged

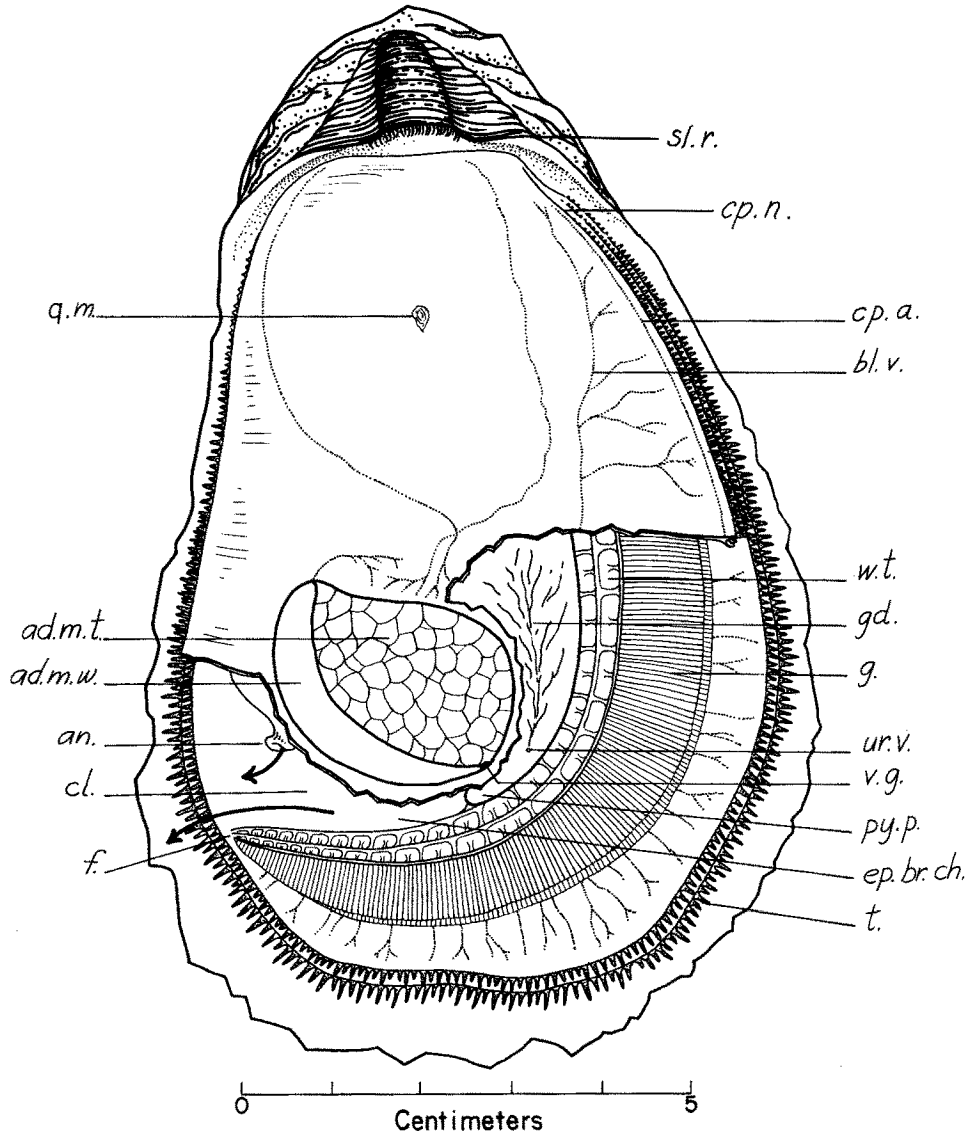

FIGURE 72.—Oyster viewed from the right side. Portion of the right mantle and the wall of the epibranchial chamber cut off to expose the gills and their water tubes, the cloaca, and the lower part of the gonad. ad.m.t.—adductor muscle, translucent part; ad.m.w.—adductor muscle, white (opaque) part; an.—anus; bl.v.—blood vessels of the mantle; cl.—cloaca (the arrow indicates the direction of the outgoing current of water); cp.a.—circumpallial artery; cp.n.—circumpallial nerve; ep.br.ch.—epibranchial chamber of the gills; f.—fusion of gills and mantle; g.—gills; gd.—gonoducts; py.p.—pyloric process; q.m.—rudimentary Quenstedt's muscle; t.—tentacles; ur.v.—opening of the urinogenital vestibule; v.g.—visceral ganglion; w.t.—water tubes of the gills. Drawn from a preserved specimen.

through the mantle and gills. The alkalinity of the shell liquor retained in the mantle cavity therefore decreases with time as the oyster remains closed. Although liquor may become slightly acid, excessive acidity is stopped by the buffering action of calcium carbonate dissolved from the shell.

The ability of the oyster to retain shell liquor is a useful adaptation to life in the intertidal zone permitting the animal to survive many days of exposure to air. It is equally useful to those oysters which live below the low water mark and are never exposed to air. By closing their shells tightly and by retaining some sea water they are able to survive unfavorable conditions caused by floods or by the temporary presence of toxic or irritating substances in the water.

The color of the surface of the mantle facing the shell is variable. Lean oysters devoid of glycogen are usually of a dull grayish color whereas "fat"

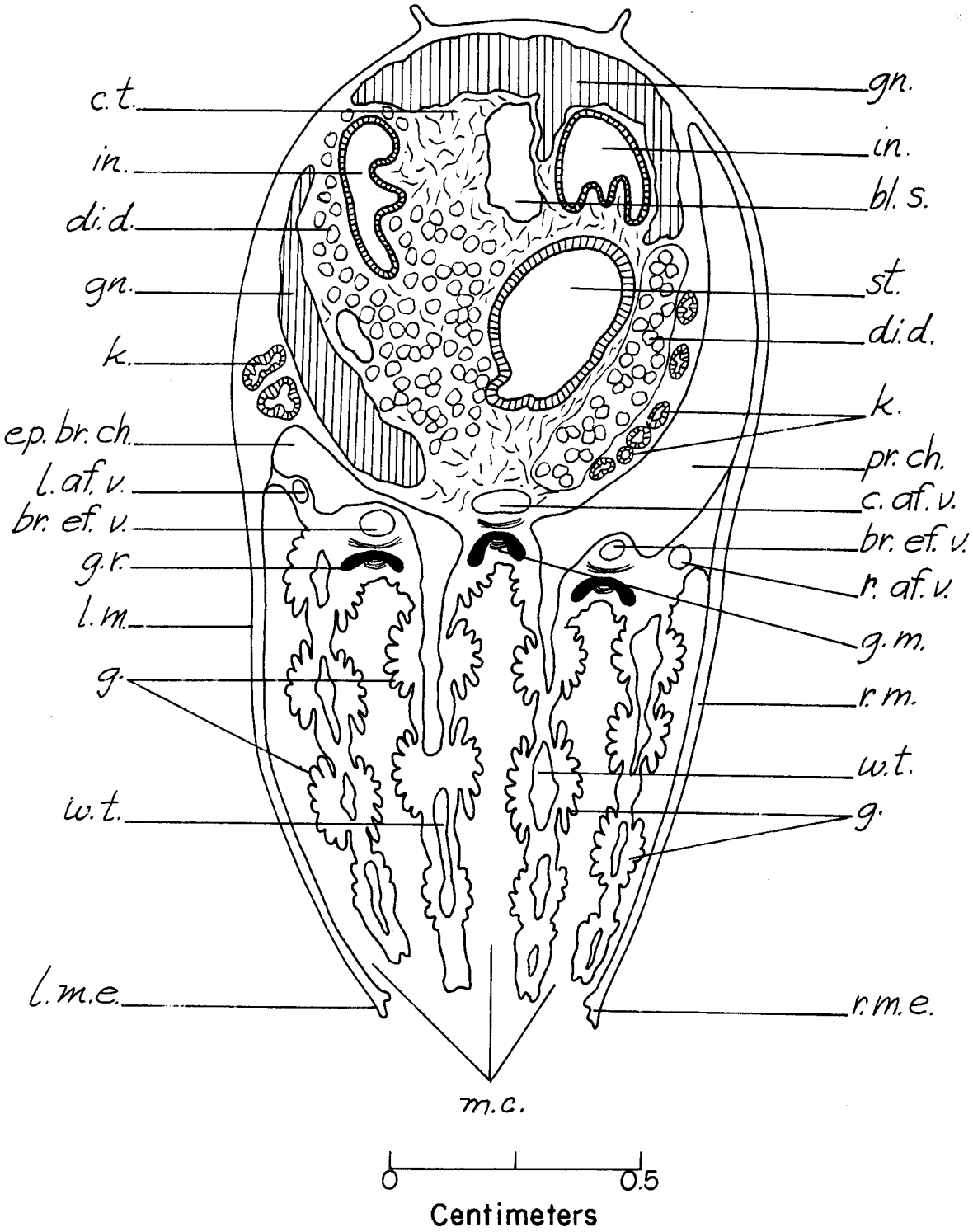

FIGURE 73.—Transverse section of the dorsal part of an adult *C. virginica* a short distance below the labial palps. Drawn semidiagrammatically from an enlarged photograph of stained section. Bl.s.—blood sinus; br.ef.v.—branchial efferent vein; c.af.v.—common afferent vein; c.t.—connective tissue; di.d.—digestive diverticula; ep.br.ch.—epibranchial chamber; g.—gills; g.m.—gill muscles; g.r.—gill rod, gn.—gonad; in.—intestine; k.—kidney; l.af.v.—lateral afferent vein; l.m.—left mantle; l.m.e.—edge of left mantle; m.c.—mantle cavity; pr.ch.—promyal chamber; r.af.v.—right afferent vein; r.m.—right mantle; r.m.e.—edge of right mantle; st.—stomach; w.t.—water tube of the gills.

oysters are white and those full of spawn are creamy-yellowish. The green color of oysters from certain localities is attributed to the accumulation of copper or to the absorption of blue-green pigment from certain diatoms upon which they feed. Mantle color is always a good indication of the condition of the mollusk.

Several ramifying blood vessels can be easily seen on the surface of the mantle (fig. 72, bl. v.). A broad blood vessel along the periphery is the circumpallial artery (fig. 72, cp. a.). A narrow and darker line immediately adjacent is a circumpallial nerve (fig. 72, cp.n.). A small, slightly pigmented depression in the dorsal end of the mantle marks the position of a nonfunctional Quenstedt's muscle (fig. 72) barely attached to the valve.

The most conspicuous element of the oyster anatomy visible after the removal of the valve is the posterior adductor muscle. This ovate organ consists of a larger dorsal, translucent portion (fig. 72, ad.m.t.) and a consistently smaller, ventral opaque part (ad.m.w.).

A semitransparent oval membrane covers the pericardium, the chamber in which the heart is suspended (fig. 71, per.). On the left side of the oyster the pericardial wall lies directly under the valve, but on the right side the large and asymmetrical promyal chamber (fig. 73, pr.ch.) separates the pericardium from the mantle.

ORGANS UNDERLYING THE MANTLE

Directly under the free edge of the mantle along the entire anteroventral side of the oyster lie the gills (fig. 72, g.). They can be exposed by cutting off the mantle along the line of its attachment to the base of the gills, or by lifting the mantle and pulling it up. If a piece of shell is sawed off at the anterior edge of the valve the corresponding portion of the mantle curls up and exposes the gills underneath. For several days the opposite fold of the mantle retains its normal position with the tentacles (t.) spread over the edge of the shell, while the curled mantle edge under the cut secretes a vertical plate. Later on the mantle fold of the intact side of the oyster also curls up and by depositing new shell material at the angle to the valve closes the gap. Cutting off a portion of one valve proved to be a useful procedure for observing the functions of the gills and mantle.

The gills consist of two pairs of lamallae or gill plates, one pair on each side (figs. 71, 72, g.). At the anterodorsal margin their free and gently curved edges touch the lower tips of the labial palps (fig. 71, l.p.) and their bases are joined to the mantle. In the ventroposterior part of the body the gills and the two lobes of the mantle join to form a channel (fig. 71, f.) which marks the entrance to the cloaca (fig. 72, cl.).

The mouth (fig. 71, m.), a narrow horizontal slot above the dorsal edges of the two posterior labial palps, lies under the hood or cap formed by the anterior fusion of the two mantle folds. It can be seen by cutting off the mantle cap and pressing down the upper (dorsal) edges of the palps.

The cloaca (fig. 72, cl.), a large funnel-shaped space between the ventral side of the adductor muscle and the gills, is a continuation of the epibranchial chamber (fig. 72, ep.br.ch.) which extends along the gills. The latter can be exposed by cutting along the wall of the cloaca, starting from the mantle junction (fig. 71, f.) and following the edge of the muscle. The epibranchial chamber extends along the base of the gills. When the dissected portions of the cloacal wall are pulled apart, the following structures are revealed: the rectum and anus (figs. 71, 72, r., an.), located on the ventroposterior border of the adductor muscle; the blunt tip of the pyloric process (fig. 72, py.p.) of the visceral mass, which projects into the epibranchial chamber; the small and almost invisible opening of the urinogenital groove or vestibule (fig. 72, ur.v.), located on the wall of the pyloric process; and the visceral ganglion (fig. 72, g.), situated in a shallow depression between the two divisions of the adductor muscle and partially covered by the pyloric process.

The heart (fig. 71, h.), seen after removal of the pericardial wall, consists of one ventricle and two pigmented auricles. Two aortae (not shown in the diagram) emerge from the tip of the ventricle, and large venous sinuses (also not shown) empty into the auricles. The slightly pigmented structure extending dorsally from the auricular side of the pericardium along the base of the gills is the organ of excretion (kidney) frequently called the organ of Bojanus (fig. 73, k.). Inasmuch as there is no doubt regarding the function of this tubular thin-walled organ it seems preferable to call it the kidney. Urine is collected in a large reservoir in the lower (ventral) part of the kidney before

being discharged through the urinogenital vestibule. On each side of the auricular part of the pericardium there is a fine opening from which a canal leads to the kidney. This renopericardial opening and the canal are difficult to see with the unaided eye.

THE VISCERAL MASS

The very short esophagus enters the large and somewhat twisted stomach, into which a wide sac containing the crystalline style also opens. The visceral mass (figs. 72, 73) occupies the dorsal half of the body, above the adductor muscle. It consists of esophagus, stomach, crystalline style sac inside the pyloric process, and intestine embedded in connective tissue. The stomach directly communicates with the digestive diverticula, a greenish mass of glandular tissue (fig. 73, st., di. d.), which completely surrounds both stomach and intestines. The intestine, after leaving the stomach, makes a loop (fig. 73, in., and fig. 197, ch. X) which ends in the rectum (fig. 71, r.) at the dorsal edge of the adductor muscle. A small rosette at the tip of the slightly protruding rectum surrounds the anus (fig. 72, an.), located in the area continually swept by the current of water from the cloaca (fig. 72, cl.).

Between the digestive diverticula and the surface epithelium lie the gonads (fig. 73, gn.). After spawning these layers disappear almost completely, being represented only by a thin germinal lining. The gonad is not visible to the unaided eye at this stage. At the time of full sexual development the layer of gonadal tissue in large specimens may reach several millimeters in thickness. Many branching channels, the gonoducts (fig. 72, gd.), through which sex cells are discharged, are clearly visible on the surface of a sexually mature specimen. They all empty into a common gonoduct leading into the urinogenital groove (fig. 72, ur. v.) from which eggs or sperm are discharged into the epibranchial chamber (ep. br. ch.). Secondary sex characters are absent.

The sex of the oyster can be recognized by microsocopic examination of the gonad. Hermaphrodites among adult *C. virginica* are rare. Out of many thousands of oysters examined in the course of my studies I have found only one oyster with the gonads containing both eggs and sperm. The European oyster, *O. edulis*, and the Olympia oyster, *O. lurida*, are hermaphroditic. (A full discussion of sex in the oyster is found in chapter XIV.)

The position of the fully developed gonad in relation to other organs of the visceral mass can best be studied in a series of transverse sections of the dorsal half of the oyster. Figure 73 shows the relative position of the organs as seen on the section made just below the labial palps. The gonad (gn.) is irregular in shape and located close to the surface of the body. The digestive diverticula (di. d.) occupy the larger part of the visceral mass between the gonad and the digestive tract itself, which at this level is represented by the stomach (st.) and two cross sections of the intestines (in.). The rest of the visceral mass consists of connective tissue (c.t.) containing irregular blood sinuses (bl. s.), which may be full of blood. The series of twisted tubules comprising the kidney (k.) is located near the surface on both sides of the body above the gills.

The large empty chambers between the gills and the visceral mass directly communicate with the water tubes (w.t.) of the gills (g.). The epibranchial chamber (ep. br. ch.) on the left side is much smaller than the corresponding chamber on the right side. The latter, called by Nelson (1938) promyal chamber (pr. ch.), extends to the dorsal end of the oyster and opens to the outside in the posterodorsal part of the body, independently of the cloaca. Water tubes (w.t.) inside the gill plates open into these chambers. Soft and delicate tissue of the gills is supported by the framework of chitinous rods, the largest being located at the base of the gills (g.). Two sets of muscles (g.m.), one below and one above the largest gill rods, control the movements of the plates. The five principal blood vessels of the gills are located above the skeletal rods: the common afferent vein (c. af. v.); two branchial efferent veins (br. ef. v.), one on each side; and two lateral afferent viens (l. af. v.), also one on each side of the oyster.

NERVOUS SYSTEM

The nervous system can be studied best by reconstructions made from sectioned material since only the principal nerves and ganglia can be revealed by dissection. The visceral ganglion (fig. 72, v.g.) is located in a slight depression on the anterior side of the adductor muscle, partially hidden by the tip of the pyloric process. It can be observed by cutting the wall of the cloaca and

of the epibranchial chamber, then placing the oyster on its posterior edge, lifting its ventral side slightly toward the observer, and pulling the dissected portions of the wall apart. The ganglion and its nerves are then visible against the background of the surrounding tissues. Some of the individual nerves, namely, the posterior pallial nerve (fig. 253, in ch. XIII, p.p.n.) and the lateral pallial nerves (l.p.n.), emerge from the posterior end of the ganglion and can be followed without much difficulty until they begin to ramify. The posterior pallial nerve follows the right side of the adductor and sends a short branch to a sense organ—a small unpigmented protuberance called the pallial or abdominal organ (p.o.). On the left side of the oyster the pallial organ is much smaller and is located much closer to the ganglion; in fact, in many oysters only the right pallial organ is present.

The anterior pallial nerve (fig. 253, in ch. XIII, a.p.n.) and branchial nerve (br.n.) leave the dorsal end of the ganglion and for some distance follow the nerve trunk which leads to the cerebral ganglia and is known as the cerebrovisceral connective (c.v.con.). The cerebral ganglia (fig. 71, c.g.) are embedded in connective tissue at the bases of the labial palps. A very thin cerebral commissure passes dorsally over the esophagus and connects the cerebral ganglia in a typical loop or ring. The circumpallial nerve (fig. 72, cp.n.) follows the circumpallial artery and can easily be seen at the edge of the expanded mantle. The other nerves emerging from the visceral and cerebral ganglia can be more conveniently studied on sectioned preparations and are described in chapter XIII.

ANATOMICAL PECULIARITIES

In several respects the anatomy of the oyster is simpler than that of other bivalves. The absence of a foot results in the lack of pedal ganglia; only the posterior adductor muscle is present, and there are no specialized organs of sight, although the animal is sensitive to change of illumination. On the other hand, the edge of the mantle is fringed with highly sensitive tentacles abundantly supplied with nerves leading to the ganglia. As in other bivalves, the nervous system is not centralized but is represented by widely separated ganglia. The structure of the cerebrovisceral connectives, of the circumpallial nerve, and other large nerves resembles more the structure of ganglia than that of the nerve, a condition which undoubtedly results in a high degree of coordination among the various parts of the organism.

In addition to performing their principal functions, several organs of the oyster also participate in other activities. The gills, for instance, are not only the organ of respiration but collect and sort food as well. The mantle is used extensively in the control of the flow of water through the body; the coordinated action of the adductor muscle, gills, and gonad is necessary for the effective discharge of eggs by the female oyster. In other animals such functions are performed by special organs, but in the evolution of the oysters the high degree of coordination developed among different parts of the body eliminates the need for specialized structures, and new and complex functions are successfully performed by synchronizing the work of the existing parts.

BIBLIOGRAPHY

AWATI, P. R., and H. S. RAI.
1931. *Ostrea cucullata* (the Bombay oyster). The Indian Zoological Memoirs on Indian Animal Types, III. Methodist Publishing House, Lucknow, India, 107 pp.

BROOKS, WILLIAM K.
1905. The oyster. A popular summary of a scientific study. 2d ed. The Johns Hopkins Press, Baltimore, Md., 225 pp.

CHURCHILL, E. P., Jr.
1920. The oyster and the oyster industry of the Atlantic and Gulf Coasts. [U.S.] Bureau of Fisheries, Report of the Commissioner of Fisheries for the fiscal year 1919, appendix 8 (Document 890), pp. 1–51.

DAHMEN, PETER.
1923. Anatomie von *Ostrea chilensis* Philippi. Jenaische Zeitschrift für Naturwissenschaft, Band 52, pp. 575–626.

GALTSOFF, PAUL S.
1958. The oyster. Encyclopaedia Britannica, 1958 ed. vol. 16, pp. 1001–1004. Encyclopaedia Britannica, Inc., Chicago, Ill.

LEENHARDT, HENRY.
1926. Quelques études sur *Grayphea angulata* (Huître du Portugal). Annales de l'Institut Océanographique, nouvelle série, tome 3, fascicule 1, pp. 1–90.

MOORE, H. F.
1898. Oysters and methods of oyster-culture. U.S. Commission of Fish and Fisheries, Part 23, Report of the Commissioner for the year ending June 30, 1897, pp. 263–338.

NELSON, THURLOW C.
1938. The feeding mechanism of the oyster. I. On the pallium and the branchial chambers of *Ostrea virginica*, *O. edulis* and *O. angulata*, with

comparisons with other species of the genus. Journal of Morphology, vol. 63, No. 1, pp. 1–61.
ORTON, JAMES H.
1937. Oyster biology and oyster-culture, being the Buckland Lectures for 1935. Edward Arnold and Co., London, 211 pp.
RANSON, GILBERT.
1943. La vie des huîtres. Histoires Naturelles-1, Collection dirigée par Jean Rostand. Gallimard, Paris, 261 pp.
ROUGHLEY, T. C.
1925. The story of the oyster. Australian Museum Magazine, vol. 2, No. 5, pp. 163–168.
YONGE, C. M.
1960. Oysters. Collins Clear-Type Press, London, 209 pp.